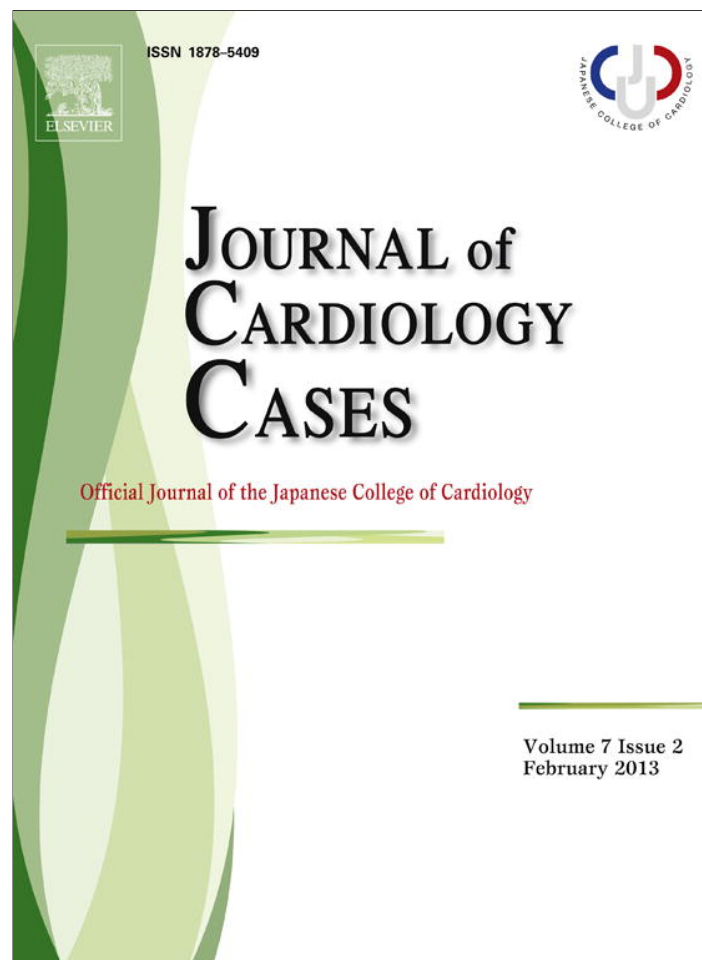


Provided for non-commercial research and education use.  
Not for reproduction, distribution or commercial use.



This article appeared in a journal published by Elsevier. The attached copy is furnished to the author for internal non-commercial research and education use, including for instruction at the authors institution and sharing with colleagues.

Other uses, including reproduction and distribution, or selling or licensing copies, or posting to personal, institutional or third party websites are prohibited.

In most cases authors are permitted to post their version of the article (e.g. in Word or Tex form) to their personal website or institutional repository. Authors requiring further information regarding Elsevier's archiving and manuscript policies are encouraged to visit:

<http://www.elsevier.com/copyright>

Contents lists available at [www.sciencedirect.com](http://www.sciencedirect.com)

## Journal of Cardiology Cases

journal homepage: [www.elsevier.com/locate/jccase](http://www.elsevier.com/locate/jccase)

## Case Report

## The case of 17-year-old male with LEOPARD syndrome

Sergey Dzemeshkevich (MD, PhD)<sup>a</sup>, Julia Frolova (PhD)<sup>a</sup>, Mikhail Betekhtin (PhD)<sup>b,\*</sup>,  
Albina Shapieva (PhD)<sup>a</sup>, Lyubov Rizun (PhD)<sup>a</sup><sup>a</sup> Department of Myocardial Dysfunction and Heart Failure, B.V. Petrovsky Russian Research Centre of Surgery RAMS, 119991, Abrikosovky per, 6, Moscow, Russia<sup>b</sup> Department of Dermatovenereology, Moscow State University of Medicine and Dentistry, 127473, Delegatskaya str. 20/1, Moscow, Russia

## ARTICLE INFO

## Article history:

Received 11 July 2012

Received in revised form

17 September 2012

Accepted 9 October 2012

## Keywords:

LEOPARD syndrome

Mutation

Cardiomyopathy

Lentiginos

## ABSTRACT

LEOPARD syndrome is a phenotypic expression of mutations in several genes: PTPN11, RAF1, and BRAF. All these genes are responsible for Ras/MARK signaling pathway, which are important for cell cycle regulation, differentiation, growth, and aging. Mutations result in anomalies of skin, skeletal, and cardiovascular systems. The LEOPARD syndrome means lentiginos, electrocardiographic conducting abnormalities, ocular hypertelorism, pulmonary stenosis, abnormal genitalia, retarded growth, and deafness. Mutations affect tyrosine proteases, which are included in the signal pathway between the cell membrane and the nucleus. This rare autosomal dominant disorder is characterized by high variability of clinical manifestations. Usually only lentiginos are common. Clinical diagnosis is based on lentiginos and 2 other symptoms; in cases without lentiginos – 3 symptoms and at least one affected first-line relative. Herein, we report the case of 17-year-old male who had idiopathic hypertrophic cardiomyopathy with left ventricular obstruction, and supraventricular and ventricular extrasystoles, class IVa, left bundle branch block, as a life-threatening manifestation of LEOPARD syndrome. For the treatment of cardiac manifestations of this syndrome, the patient underwent two interventions: (1) mitral valve replacement by mechanical valve Optiform number 27 with surgical resection of left ventricular outflow tract and subaortic membrane excision; (2) implantable cardioverter-defibrillator therapy.

**<Learning objective:** Explain the abbreviation L.E.O.P.A.R.D. (Lentiginos, Electrocardiographic conducting abnormalities, Ocular hypertelorism, Pulmonary stenosis, Abnormal genitalia, Retarded growth, and Deafness). Suspect the signs of L.E.O.P.A.R.D.-syndrome. Realize the etiology. Evaluate probability of this congenital disease on the ground of the clinical manifestations and laboratory data. Measure the significance for health of changes of organs and systems. Choose the main and dangerous manifestation of L.E.O.P.A.R.D.-syndrome. Select the best way for treatment such patients.>

© 2012 Japanese College of Cardiology. Published by Elsevier Ltd. All rights reserved.

## Introduction

LEOPARD is an acronym for this syndrome's manifestations (Lentiginos, ECG conducting abnormalities, Ocular hypertelorism, Pulmonary stenosis, Abnormal genitalia, Retarded growth and Deafness.). This acronym was introduced by Gorlin in 1969. LEOPARD syndrome is also known as Gorlin syndrome II, Lentiginos profusa syndrome or Cardiocutaneous syndrome, and caused by gene mutation. In 1936 Zeisler and Becker described the syndrome in a 24-year-old woman, who suffered from progressive generalized lentiginos, hypertelorism, pectus carinatum and prognathism. Rosen reported about the first familial cases in twins; Pipkin reported about 8 persons from a large 3-generation pedigree. The association of the syndrome with cardiac abnormalities and short stature was made by Moynahan in 1962. Frequency of

this disease is rare and is not yet possible to assess the epidemiology.

## Case report

In January 2012 the 17-year-old male was hospitalized for mitral valve replacement and implantation of cardioverter defibrillator. On physical examination, he was 164 cm, 41 kg, with an asthenic figure. There were multiple lentiginos on the skin, located throughout the body, legs 2 spots (dark-brown) larger than 1.5 cm, hyper elasticity skin, acrocyanosis of the lower extremities, a few keloid scars after surgery, and several atrophic scars. There was facial dysmorphism and low-set ears. In addition, there was acinar chest, kyphoscoliosis of the thoracolumbar spine, and joint hyper mobility (Fig. 1a and b). The heart rate was 72 per min and the blood pressure was 90/50 mmHg. His medical history included the fact that he was a premature infant with idiopathic hypertrophic subaortic stenosis. Chest deformation and dark-brown spots on the legs were diagnosed after birth. Multiple lentiginos on the

\* Corresponding author. Tel.: +7 916 552 02 46; fax: +7 499 246 89 88.

E-mail address: [krizaliy@mail.ru](mailto:krizaliy@mail.ru) (M. Betekhtin).

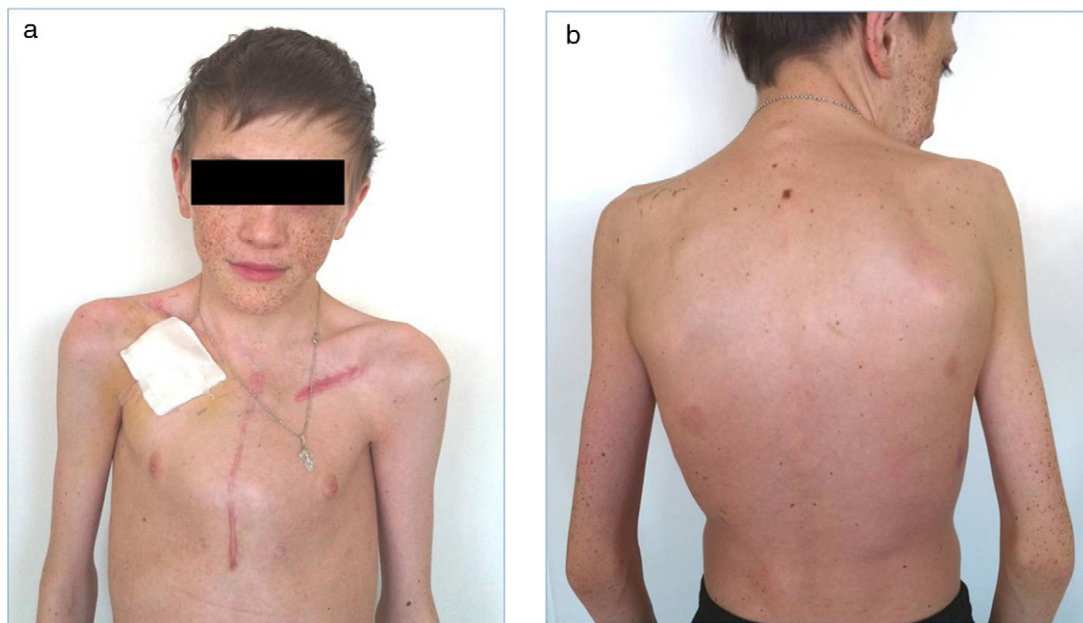


Fig. 1. (a and b) 17-year-old patient with LEOPARD syndrome.

face and body appeared since he was 6 years of age. At the same time, chest deformation was aggravated and feet deformations were noted. During physical development, retardation of growth was marked. The patient was noted to have significant deterioration including reduced tolerance to physical and mental stress, heart disturbances, and brief episodes of unconsciousness since 2002.

The clinical evaluation of LEOPARD syndrome was based on an electrocardiogram (ECG), dynamic ECG (Holter monitor), a chest

X-ray, an echocardiogram, and genetic testing. He was hospitalized for implantable cardioverter-defibrillator therapy.

During the hospital stay, ECG showed: electrical axis of heart deviation to the left, left bundle branch block, left atrial hypertrophy, left ventricular hypertrophy, and overload (Fig. 2).

On echocardiography there was left atrial dilation; normal and uniform global contractility; left ventricular hypertrophy of free right ventricular wall and septum, with obstruction outflow tract ( $V_{max} = 5.4$  m/s, peak gradient = 117/61 mmHg); right atrium and

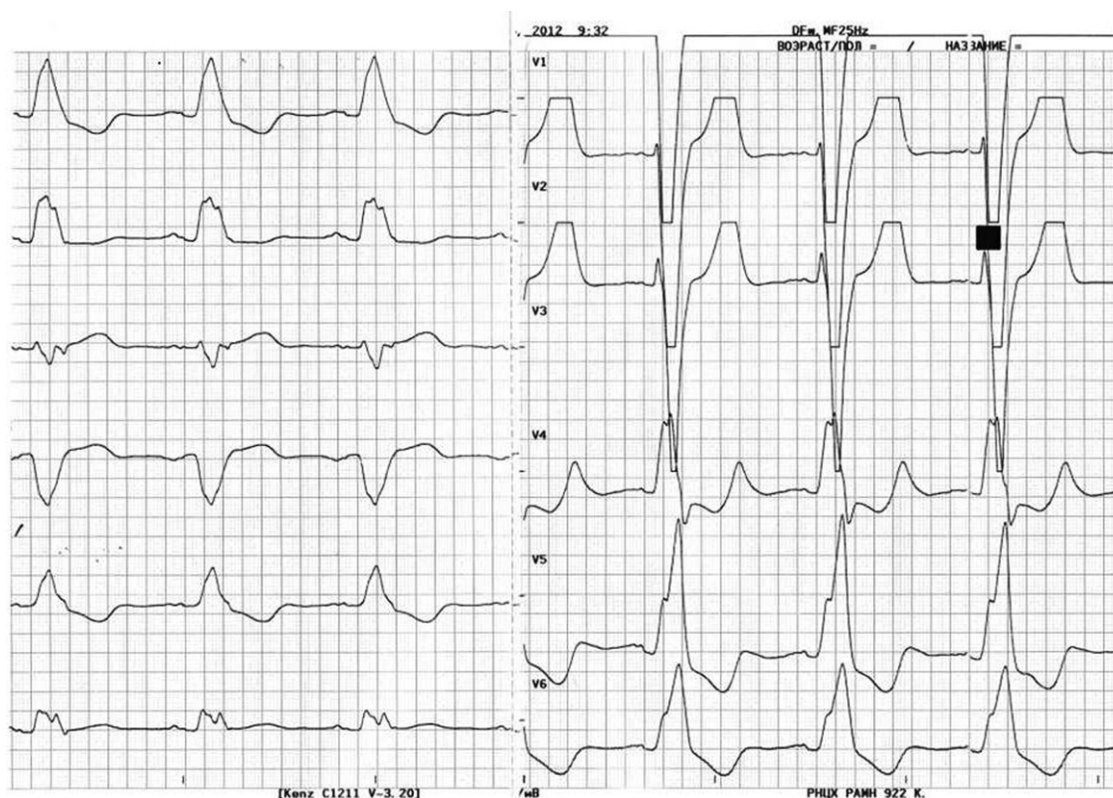
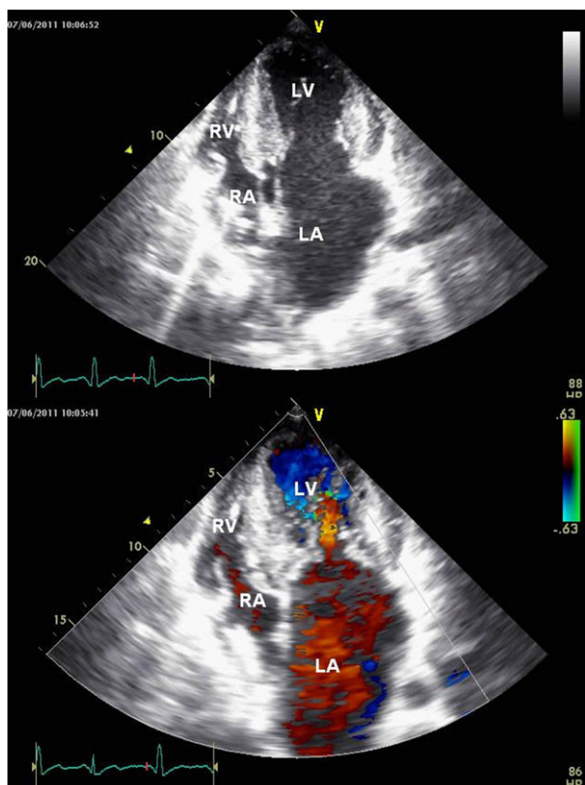


Fig. 2. Electrocardiogram showing sinus rhythm with horizontal axis of the heart, left bundle branch block, and left atria and left ventricular hypertrophy.





**Fig. 3.** Two-dimensional echocardiogram after mitral valve replacement: showing a dilated left atrium and left ventricle hypertrophy of free right ventricular wall and septum. Color Doppler showed hemodynamic parameters and function of prosthetic mitral valve is not violated. LA, left atrium; LV, left ventricle; RA, right atrium; RV, right ventricle.

right ventricle were of normal size; severe mitral regurgitation; mild tricuspid valve regurgitation; and diastolic dysfunction of left ventricular type III (Fig. 3).

Dynamic ECG (Holter monitor) showed sinus tachycardia throughout the recording period; normal physiological heart rate decrease during night sleep; 25 supraventricular extrasystoles and 118 ventricular extrasystoles – class IVa.

Chest X-ray examination showed signs of pulmonary congestion. Heart increased in size due to both atria and right ventricle. Left atria shadow deflected barium-filled gullet in an arc of large radius, beyond the shadow of the right contour of heart, on the left contour of the heart there was marked bulging of the arc of the left atrial auricle. The functional features of mitral insufficiency were determined.

Computed tomography showed that mediastinal organs were well differentiated in the carinate chest. Heart increased in size. Pericardium with separation layers on the parietal wall of the right ventricle to 9.0 mm. The superior vena cava – 1.7 cm, pulmonary trunk – 3.1 cm, the right and left pulmonary artery – 2.1 cm and left – 2.1 cm, respectively. The inferior vena cava – 2.6 cm. Left ventricular end-diastolic dimension – 2.2 cm, right ventricle – 1.9 cm, right atrium – 4.4 cm × 3.9 cm. Thickness of ventricular septum (basal segments) in diastole: anterior – 2.6 cm, inferior – 2.5 cm. The thickness of the ventricular myocardium: anterolateral – 2.3 cm, inferolateral – 2.3 cm. The thickness of the left ventricular myocardium in the apical part in diastole – 0.97 cm. Left ventricular outflow tract – 18 mm, in the lumen of the vena cava superior and right atrial cavity are linear structures of the electrodes.

Genetic study showed mutations in exon 12 of the gene PTPN11 and changes in the adjacent intron regions of the gene RAF1 (5, 6, 13, 15 introns).

Medications the patient was taking before surgery were: beta-blockers, diuretics, and antiarrhythmic drug. Although the patient was compensated by drug therapy, the need for surgery was necessary in view of the episodes of loss of consciousness.

The operation of mitral valve replacement by mechanical valve with surgical resection of left ventricular outflow tract and subaortic membrane excision was performed successfully. After that, a dual-chamber cardioverter defibrillator (ICD) with right ventricular and right atria electrodes was implanted. Implanted ICD systems are an effective way of preventive therapy for life-threatening arrhythmias and sudden death [3,10,11], and therefore in the above case, the final stage of surgery was implanted ICD.

When checking the value of ICD exhibited mode DDD, base frequency 50–130 min, the threshold of stimulation: right atrium – 0.6 V. Right ventricle – 0.6 V.

The patient was treated with antibacterial, anti-inflammatory, antianginal, antiarrhythmic, diuretic, and anticoagulant drugs. Early postoperative period was uneventful.

Control laboratory studies have shown: activated partial thromboplastin time 46.9 (27–37)s, fibrinogen 2.27 g/l, prothrombin index 38.73%, international normalized ratio 2.89 (1.0–1.3). The other indicators were normal.

## Discussion

LEOPARD syndrome is a rare condition, which is caused by different missense-mutations in one of the 3 genes (PTPN1 = 90%, RAF1 < 5%, BRAF < 5%) and subsequent disturbances (Fig. 4).

One feature of the natural history of LEOPARD syndrome is an increased risk of neoplasia. Genes responsible for the development of the LEOPARD syndrome are a family of proto-oncogenes and mutations in them are associated with the risk of lymphoproliferative disease [8]. For example, different mutations in the PTPN11 gene may cause allelic series of diseases with different clinical phenotypes, but an increased risk of cancer. So an important part of the follow-up of patients with LEOPARD syndrome is a planned control of blood cell composition and consulting an oncologist annually.

Last investigations showed molecular mechanisms of LEOPARD syndrome, but now its prevention is possible only in experiments. This rare autosomal dominant disorder is characterized by high variability of clinical manifestations. According to some researchers, the number of patients is much greater, and the evidence of symptoms increases with age [7,11,14,17].

The title of the syndrome L.E.O.P.A.R.D. is derived from the initial letters of the major signs and symptoms of the syndrome, according to Gorlin et al. [2,4,5]: Lentigo – lentiginos to 100%. ECG – electrocardiogram abnormalities (75–80%), among them: hypertrophy of the left ventricle, or both ventricles (46%) [1], appearance of Q wave (19%), elongation of QTc (23%) and impaired repolarization (42%) [9], conduction disorders (23%) and P-wave abnormalities (19%). Ocular hypertelorism – 75%. Pulmonic stenosis – 95%. Abnormalities of genitalia – 50%. Genital anomalies include agenesis or hypoplasia of the gonads and hypogonadism. Retardation of growth – 40–50%. In 50% of cases there are winged scapula, 35% – cervical pterygium. Notes funnel or pigeon chest deformity. Deafness – 15–25% [2].

Clinical diagnosis is based on lentiginos and 2 other symptoms, in cases without lentiginos – 3 symptoms and at least one affected first-line relative [22,23].

Lentigo is usually multiple spots ranging in size from 1.5 mm to 2 cm in diameter, round or elongated, yellowish or brownish-black. They are somewhat compacted, sometimes raised above the skin surface. Edges of the spots have the shape of teeth or are smooth. Lentigo spots can affect not only the skin, but mucous membranes. Common forms of lentiginos often defined as lentiginosis. Such

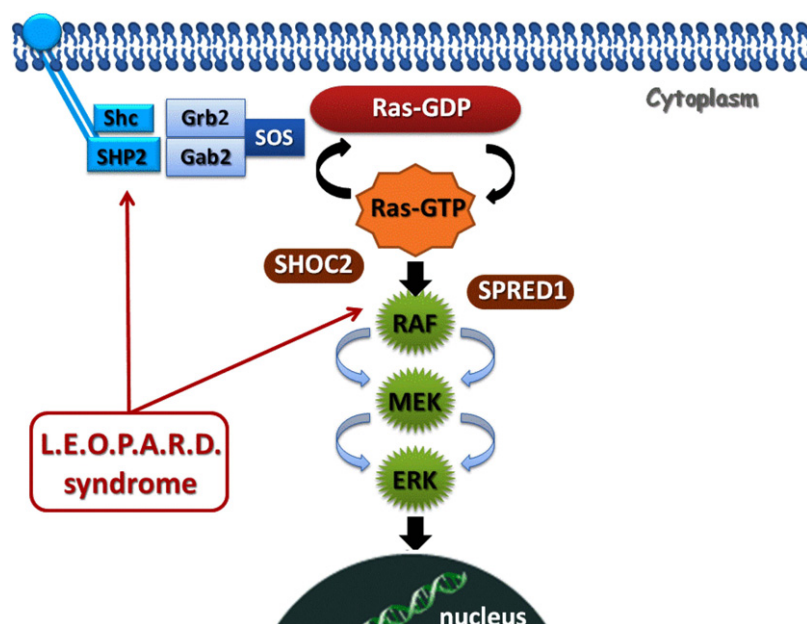


Fig. 4. Disturbances of intracellular signal transduction in the LEOPARD syndrome.

patients may have thousands of lentigines by the time they reach puberty. Congenital lentiginosis is inherited in an autosomal dominant manner and is characterized by the appearance on the skin of the child of many small round brown spots. Biopsy of lentigo shows a canthos is, a large amount of melanin and melanocytes in the basal layer of the epidermis, in the upper part of the derm is there are melanophores and small perivascular infiltrates of lymphocytes [13,14,22]. The etiopathogenesis of this clinical feature remains unknown. Some authors consider that LEOPARD syndrome patients have high melanocytic activity and increased beta-adrenergic effector activity in the myocardium [22]. Perhaps a peculiarity of exchange of tyrosine, from which melanin is formed, also plays a role.

In un complicated and feebly marked cases of lentiginosis treatment is not obligatory. Since lentigines are subject to constant trauma, it is recommended to remove them by surgery or with a laser or cryodestruction. Usage of topical creams is also possible. Cream hydroquinone and cream tretinoin can brighten up lentigines during 2–4 months.

Multiple lentigines syndrome is an indicator of both LEOPARD and many genetic diseases that share similar etiopathogenic mechanisms. Despite the fact that the incidence of these diseases is rare, physicians should pay attention to the presence or absence of lentigines.

For instance, lentigines over the entire surface of the body and oral mucosa are also described in the Carney complex. But there are not lentigines on the oral mucosa in the LEOPARD syndrome [16].

Life-threatening conditions are associated with pathology of the cardiovascular system. Cardiac abnormalities include electrocardiographic conduction defects and anatomical malformations; electrocardiographic conduction abnormalities are especially frequent. Axial deviation, prolonged PR interval, left anterior hemiblock (LAH), bundle-branch block, and complete heart block (CHB) are also described [22].

Hypertrophic cardiomyopathy (HCM) is a frequent autosomal dominant disease characterized by hypertrophy (thickening) of the left wall and/or right ventricle. The prevalence in a population is not less than 0.2% (1:500 individuals). The classification of the American Heart Association, 2006 [12], identifies the primary HCM (developing as a result of mutations in sarcomeric protein genes)

and secondary HCM, which is part of a symptom of many genetic syndromes (e.g. Noonan, LEOPARD, storage diseases, etc.) [15].

HCM is found in as many as 80% of patients and sometimes causes death, while pulmonic stenosis is present in about 40% of patients. A variety of anomalies affecting the patient forces doctors to use the full range of interventions, in compliance with the existing pathology.

Patients with HCM have a high risk of ventricular tachyarrhythmias and sudden cardiac death, so that all patients should undergo risk stratification for sudden cardiac death and the initial stages of the survey should identify tachyarrhythmia episodes, as well as unexplained syncope in history [3,10,21].

One of the most effective treatments for obstructive HCM is a form of surgery [6,18]. The two main common surgical treatments for HCM are septal myectomy [14,18,19] and alcohol septal ablation [20]. The success of the latter depends on the variability of anatomy branches septal perforators that in 20–25% of cases do not achieve the desired effect [19]. With common forms of HCM and, especially when combined with other intracardiac pathologies, the only method of treatment is surgery under extracorporeal circulation.

This syndrome is still not sufficiently studied, and remains a puzzle to researchers. Sometimes, there are reports of possible new symptoms of the syndrome [24].

Due to the fact that the syndrome is rare, it is difficult to determine what other symptoms can be referred to this syndrome. Since only a small number of cases have been described, one or two cases can significantly change the statistics.

## References

- [1] Coppin BD, Temple IK. Multiple lentigines syndrome (LEOPARD syndrome or progressive cardiomyopathic lentiginosis). *J Med Genet* 1997;34:582–6.
- [2] Digilio MC, Pacileo G, Sarkozy A, Limongelli G, Conti E, Cerrato F, Marino B, Pizzuti A, Calabrò R, Dallapiccola B. Familial Aggregation of genetically heterogeneous hypertrophic cardiomyopathy: a boy with LEOPARD syndrome due to PTPN11 mutation and his nonsyndromic father lacking PTPN11 mutations. *Birth Defects Res A Clin Mol Teratol* 2004;70:95–8.
- [3] Elliott PM, Poloniecki J, Dickie S, Sharma S, Monserrat L, Varnava A, Mahon NG, McKenna WJ. Sudden death in hypertrophic cardiomyopathy: identification of high risk patients. *J Am Coll Cardiol* 2000;36:2212–8.
- [4] Gorlin RJ, Anderson RC, Blaw M. Multiple lentigines syndrome. *Am J Dis Child* 1969;117:652–62.

- [5] Gorlin RJ, Anderson RC, Moller JH. The Leopard (multiple lentiginos) syndrome revisited. *Birth Defects Orig Artic Ser* 1971;7:110–5.
- [6] Dearani JA, Ommen SR, Gersh BJ, Schaff HV, Danielson GK. Surgery insight: septalmyectomy for obstructive hypertrophic cardiomyopathy – the Mayo Clinic experience. *Nat Clin Pract Cardiovasc Med* 2007;4:503–12.
- [7] Jopling C, van Geemen D, den Hertog J. Shp2 knockdown and Noonan/LEOPARD mutant Shp2-induced gastrulation defects. *PLoS Genet* 2007;12:e225.
- [8] Kalidas K, Shaw AC, Crosby AH, Newbury-Ecob R, Greenhalgh L, Temple IK, Law C, Patel A, Patton MA, Jeffery S. Genetic heterogeneity in LEOPARD syndrome: two families with no mutations in PTPN11. *J Hum Genet* 2005;50:21–5.
- [9] Limongelli G, Pacileo G, Marino B, Digilio MC, Sarkozy A, Elliott P, Versacci P, Calabro P, De Zorzi A, Di Salvo G, Syrris P, Patton M, McKenna WJ, Dalapiccola B, Calabro R. Prevalence and clinical significance of cardiovascular abnormalities in patients with the LEOPARD syndrome. *Am J Cardiol* 2007;100:736–41.
- [10] Maki S, Ikeda H, Muro A, Yoshida N, Shibata A, Koga Y, Imaizumi T. Predictors of sudden cardiac death in hypertrophic cardiomyopathy. *Am J Cardiol* 1998;82:774–8.
- [11] Maron BJ, Spirito P, Shen WK, Haas TS, Formisano F, Link MS, Epstein AE, Almquist AK, Daubert JP, Lawrenz T, Boriani G, Estes III NA, Favale S, Piccininno M, Winters SL, et al. Implantable cardioverterdefibrillators and prevention of sudden cardiac death in hypertrophic cardiomyopathy. *JAMA* 2007;298:405–12.
- [12] Maron BJ, Elliott P. Is the 2006 American Heart Association classification of cardiomyopathies the gold standard. The 2006 American Heart Association classification of cardiomyopathies is the Gold Standard. *Circ Heart Fail* 2008;1:72–6.
- [13] Nordlund JJ, Lerner AB, Braverman IM, McGuire JS. The multiple lentiginos syndrome. *Arch Dermatol* 1973;107:259–61.
- [14] Ommen SR, Maron BJ, Olivetto I, Maron MS, Cecchi F, Betocchi S, Gersh BJ, Ackerman MJ, McCully RB, Dearani JA, Schaff HV, Danielson GK, Tajik AJ, Nishimura RA. Long-term effects of surgical septalmyectomy on survival in patients with obstructive hypertrophic cardiomyopathy. *J Am Coll Cardiol* 2005;46:470–6.
- [15] Elliott P, Lambiase PD, Kumar D, editors. Oxford specialist handbooks in cardiology. Inherited cardiac disease. Oxford: Oxford University Press; 2011. p. 405.
- [16] Porciello R, Divona L, Strano S, Carbone A, Calvieri C, Giustini S. Leopard syndrome. *Dermatol Online J* 2008;14:7.
- [17] Stewart RA, Sanda T, Widlund HR, Zhu S, Swanson KD, Hurley AD, Bentires-Alj M, Fisher DE, Kontaridis MI, Look AT, Neel BG. Phosphatase-dependent and -independent functions of Shp2 in neural crest cells underlie LEOPARD syndrome pathogenesis. *Dev Cell* 2010;18:750–62.
- [18] Schaff HV, Dearani JA, Ommen SR, Sorajja P, Nishimura RA. Expanding the indications for septalmyectomy in patients with hypertrophic cardiomyopathy: results of operation in patients with latent obstruction. *J Thorac Cardiovasc Surg* 2012;143:303–9.
- [19] Smedira NG, Lytle BW, Lever HM, Rajeswaran J, Krishnaswamy G, Kaple RK, Dolney DO, Blackstone EH. Current effectiveness and risks of isolated septalmyectomy for hypertrophic obstructive cardiomyopathy. *Ann Thorac Surg* 2008;85:127–33.
- [20] Sorajja P, Valeti U, Nishimura RA, Ommen SR, Rihal CS, Gersh BJ, Hodge DO, Schaff HV, Holmes Jr DR. Outcome of alcohol septal ablation for obstructive hypertrophic cardiomyopathy. *Circulation* 2008;118:131–9.
- [21] Spirito P, Autore C, Rapezzi C, Bernabò P, Badagliacca R, Maron MS, Bongioanni S, Cocolo F, Estes NA, Barillà CS, Biagini E, Quarta G, Conte MR, Bruzzi P, Maron BJ. Syncope and risk of sudden death in hypertrophic cardiomyopathy. *Circulation* 2009;119:1703–10.
- [22] Tartaglia M, Martinelli S, Stella L, Bocchinfuso G, Flex E, Cordeddu V, Zampino G, Burgt I, Palleschi A, Petrucci TC, Sorcini M, Schoch C, Foa R, Emanuel PD, Gelb BD. Diversity and functional consequences of germline and somatic PTPN11 Mutations in human disease. *Am J Human Genet* 2006;78:279–90.
- [23] Voron DA, Hatfield HH, Kalkhoff RK. Multiple lentiginos syndrome. Case report and review of the literature. *Am J Med* 1976;60:447–56.
- [24] Yagubyan M, Panneton JM, Lindor NM, Conti E, Sarkozy A, Pizzuti A. LEOPARD syndrome: a new polyaneurysm association and an update on the molecular genetics of the disease. *J Vasc Surg* 2004;39:897–900.